

# MEDIAL PATELLOFEMORAL LIGAMENT RECONSTRUCTION

Nirav H. Amin, MD

T. Sean Lynch, MD

Ronak M. Patel, MD

Nimit Patel, MD

Paul Saluan, MD

*Investigation performed at the Department of Orthopaedic Surgery, Cleveland Clinic, Cleveland, Ohio*

» Recurrent patellar instability continues to be a challenging problem for surgeons as more patients are being diagnosed and managed each year.

» The majority of complications are secondary to technical error; thus, it is imperative that the surgeon has a thorough understanding of the anatomy and biomechanics of the medial patellofemoral ligament.

» The indications and algorithm for treatment continue to evolve.

» The ultimate goal for recurrent patellar instability should be to restore the native biomechanics and stability of the patellofemoral joint.

In the general population, the overall incidence of acute patellar dislocation is 5.8 per 100,000 people in the United States<sup>1</sup>. The rate of patellar dislocation is estimated to be highest in the age group of ten to seventeen years, with reported rates of 29% to 43%<sup>1-3</sup>. Women have a 33% increased prevalence of acute patellar dislocation compared with men<sup>1</sup>. Patellar instability typically occurs in patients with several anatomic risk factors, including both soft-tissue and osseous abnormalities. Conlan et al. studied twenty-five cadaveric specimens to analyze soft-tissue restraints associated with patellar instability and found the medial patellofemoral ligament to be a critical medial soft-tissue restraint in preventing lateral instability<sup>4</sup>. Furthermore, biomechanical and radiographic findings have led many surgeons to state that disruption of the medial patellofemoral ligament is the “essential lesion” required for patellar dislocation<sup>1,4-7</sup>. Disruption of the medial patellofemoral ligament was diagnosed on magnetic resonance imaging (MRI) in

twenty-six (96%) of twenty-seven patients<sup>8</sup>; the lesion most commonly occurs at the femoral attachment site<sup>9,10</sup> (Fig. 1). In addition, the deep capsular layer, the medial patellomeniscal ligament, and the medial patellotibial ligament all have been found to contribute to the soft-tissue stabilization of the patella against lateral dislocation<sup>4</sup>.

The stability of the patella is also determined by anatomic osseous constraints such as the morphology of the femoral trochlea and the alignment of the tibia relative to the femur. In the study by Amis et al., in vitro testing showed that the femoral trochlear lateral wall is the primary restraint to lateral translation once the patella engages the trochlea during knee flexion<sup>6</sup>. Therefore, the treatment of chronic patellar instability has been greatly debated. Numerous operative techniques for reconstruction of the medial patellofemoral ligament have been described; however, a consensus standard of care has yet to be defined in the literature. A medial patellofemoral ligament reconstruction creates a passive restraint to lateral displacement

**Disclosure:** None of the authors received payments or services, either directly or indirectly (i.e., via his or her institution), from a third party in support of any aspect of this work. None of the authors, or their institution(s), have had any financial relationship, in the thirty-six months prior to submission of this work, with any entity in the biomedical arena that could be perceived to influence or have the potential to influence what is written in this work. Also, no author has had any other relationships, or has engaged in any other activities, that could be perceived to influence or have the potential to influence what is written in this work. The complete **Disclosures of Potential Conflicts of Interest** submitted by authors are always provided with the online version of the article.

COPYRIGHT © 2015 BY THE JOURNAL OF BONE AND JOINT SURGERY, INCORPORATED

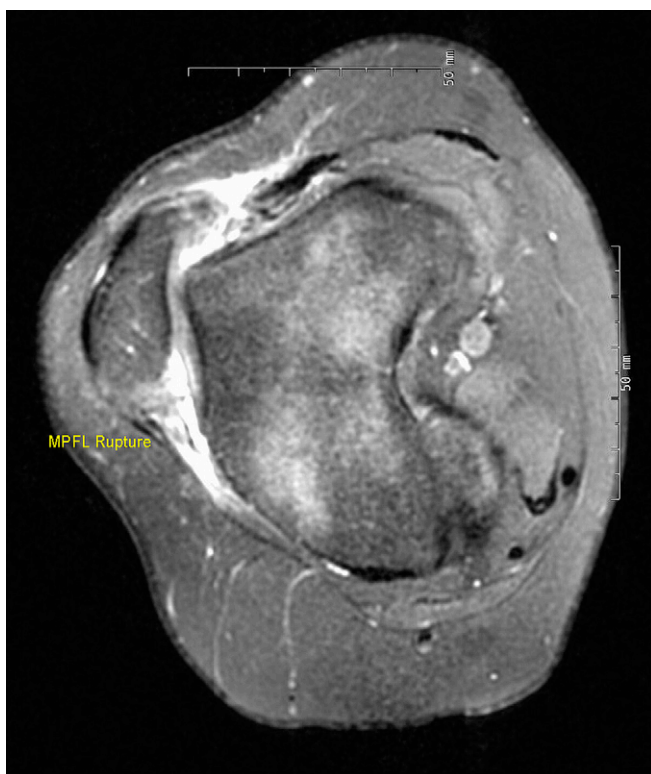

Fig. 1  
T2-weighted axial MRI showing disruption of the medial patellofemoral ligament (MPFL), with increased signal along the previous site of insertion of the ligament.

of the patella and has become an accepted technique for the restoration of patellofemoral stability<sup>11-13</sup>. On the other hand, trochleoplasty and osseous transfers also have been used to correct the underlying abnormality leading to patellar instability. The purpose of this article is to review medial patellofemoral ligament reconstruction both as a viable stand-alone procedure and as a complementary component of a larger salvage operation involving other soft-tissue and/or osseous abnormalities in patients with chronic patellar instability. In addition, an operative technique guide is provided along with the senior author's preferred method.

### Anatomy and Biomechanics

As the frequency of medial patellofemoral ligament reconstruction continues to increase, it is important to understand the anatomy and biomechanics of the medial patellofemoral ligament as well as the injury patterns that occur. Warren and Marshall described three fascial layers on the medial side of the knee: the most superficial layer includes the vastus medialis muscle and sartorial fascia, the

intermediate layer comprises the medial patellofemoral ligament and the superficial medial collateral ligament, and the third layer involves the joint capsule and the medial patellotibial ligament<sup>14</sup>.

The footprints of the femoral and patellar attachments of the medial patellofemoral ligament have been well described<sup>4,6,15-17</sup>. Nomura et al. found the origin of the medial patellofemoral ligament to be distal to the adductor tubercle and superior and posterior to the medial epicondyle<sup>15</sup>. In a cadaveric study, LaPrade et al. identified the femoral attachment to be 1.9 mm anterior and 3.8 mm distal to the adductor tubercle, arising between the medial epicondyle and the adductor tubercle<sup>16</sup>. This landmark can be palpated intraoperatively. Steensen et al., in a study of eleven cadaveric knees, reported the mean width of the femoral attachment of the medial patellofemoral ligament to be 15.4 mm<sup>17</sup>.

The insertion of the medial patellofemoral ligament onto the patella has been well described. Two cadaveric studies have demonstrated the patellar

insertion to be on the superior half of the medial border of the patella<sup>4,6</sup>. Steensen et al. found the mean width of the medial patellofemoral ligament attachment on the patella to be  $17 \pm 3.0$  mm<sup>17</sup>. Furthermore, the superior edge of the medial patellofemoral ligament inserted a mean of 6.1 mm from the superior pole of the patella and the inferior edge inserted a mean of 23.1 mm from the superior pole of the patella. Overall, the medial patellofemoral ligament footprint on the patella was 38.8% of the total patellar length.

Biomechanically, the medial patellofemoral ligament is the primary soft-tissue stabilizer of the patella as it prevents lateral translation of the patella during the first 30° of flexion<sup>6,18</sup>. As knee flexion increases from 0° to 30°, the medial patellofemoral ligament guides the patella into the trochlear groove. At 30° of flexion, the patella should be centered in the trochlear groove and should allow <1 cm of lateral translation<sup>19</sup>. Beyond 30° of flexion, the trochlea becomes the primary stabilizer of the patella. Amis and colleagues reported an

increase in lateral patellar translation when the lateral trochlear wall is flattened, further demonstrating the importance of the trochlea for patellar stability<sup>6,20</sup>.

### Indications

The indications for operative reconstruction of the medial patellofemoral ligament and the addition of concomitant soft-tissue and osseous procedures continue to be debated. In a randomized controlled trial, Palmu et al. and Hennrikus and Pylawka reported no significant difference in long-term subjective or functional results between operative and nonoperative treatment of first-time traumatic patellar dislocations<sup>21,22</sup>. As a result, nonoperative treatment continues to be the standard of care for first-time traumatic patellar dislocation except in cases involving osteochondral fractures, vastus medialis avulsions, large osteochondral fragments, or concomitant intra-articular abnormalities such as meniscal tears<sup>9,23</sup>. Conservative treatment is generally successful, with the reported rate of redislocation after simple patellar dislocation ranging from 15% to 44%<sup>1,24-26</sup>. Currently, most surgeons think that medial patellofemoral ligament reconstruction is indicated when there is recurrent instability with more than two documented dislocations or when conservative treatment has failed<sup>9,22,23,27-29</sup>.

The cause of patellar instability is multifactorial, including trochlear dysplasia, malalignment of the tibia relative to the femur, and patella alta<sup>6,18,30,31</sup>. The role of trochlear dysplasia in the setting of patellar dislocation is controversial<sup>32,33</sup>. Steiner et al., in a study of thirty-four patients who were managed with isolated medial patellofemoral ligament reconstruction for the treatment of chronic patellar instability associated with trochlear dysplasia, found substantial improvements in clinical outcome scores and no recurrent dislocations<sup>34</sup>. The authors concluded that medial patellofemoral ligament reconstruction alone can be efficacious even in the context of trochlear dysplasia. However, this opinion remains

controversial. Nelitz et al. noted that one of the primary reasons for failure after a medial patellofemoral ligament reconstruction was a higher tibial tubercle-trochlear groove distance that was not addressed during the index procedure, leading to increased forces on the reconstruction and, as a result, unsuccessful clinical outcomes<sup>35</sup>. Banke et al., in a study of seventeen patients with a severely dysplastic trochlea and chronic patellofemoral instability, described successful results at a minimum of two years after trochleoplasty combined with medial patellofemoral ligament reconstruction<sup>36</sup>. Koh and Stewart addressed osseous misalignment with a tibial tubercle osteotomy to unload the articular cartilage in addition to aiding stability<sup>37</sup>. Many surgeons, including the senior author, continue to recommend a primary osseous procedure with or without medial patellofemoral ligament reconstruction in the setting of high-grade trochlear dysplasia.

Wagner et al. reported on fifty patients with varying risk factors, including trochlear dysplasia, who underwent isolated medial patellofemoral ligament reconstruction<sup>32</sup>. The authors noted an inverse relationship between the degree of trochlear dysplasia and clinical outcomes and concluded that an osseous procedure should be considered. Likewise, Fucentese et al. found that 75% (thirty-three) of forty-four patients had a negative apprehension test after undergoing a trochleoplasty alone, suggesting the effectiveness of a solitary osseous procedure<sup>38</sup>. Finally, in a prospective two-year follow-up study, Banke et al. reported excellent clinical and radiographic outcomes in all but one of their patients who had undergone a combined trochleoplasty and medial patellofemoral ligament reconstruction<sup>36</sup>. Schöttle et al. also reported excellent clinical and radiographic results with a similar procedure<sup>39</sup>.

In the setting of patellar instability, malalignment refers to external tibial torsion and/or excessive femoral anteversion. A tibial tuberosity-trochlear groove distance of  $>20$  mm suggests

patellar malalignment and can generally be addressed with a tibial tuberosity transfer or femoral derotation osteotomy to restore proper alignment between the trochlea and the tubercle<sup>2,40,41</sup>. Similar to trochlear dysplasia, there is no consensus regarding the treatment of malalignment in the setting of patellar instability.

Schöttle et al. reported successful clinical and radiographic results in a study of fifteen patients who underwent medial patellofemoral ligament reconstruction, which was combined with medialization of the tibial tuberosity if the preoperative tibial tubercle-trochlear groove distance was  $>15$  mm<sup>40</sup>. However, whether isolated medial patellofemoral ligament reconstruction can provide successful results in patients with malalignment is still debatable. Matsushita et al., in a retrospective review of thirty-four patients who underwent medial patellofemoral ligament reconstruction, reported no significant difference in clinical outcomes between the patients in whom the tibial tubercle-trochlear groove distance was  $<20$  mm ( $n = 15$ ) and those in whom it was  $>20$  mm ( $n = 19$ )<sup>42</sup>. These two studies demonstrate the controversy regarding the treatment of recurrent patellar instability in patients with an elevated tibial tubercle-trochlear groove distance.

Overall, the literature lacks well-controlled randomized studies in which medial patellofemoral ligament reconstruction alone is compared with medial patellofemoral ligament reconstruction combined with additional osseous or soft-tissue procedures. Many recent studies have not clearly differentiated between trochlear dysplasia and malalignment when investigating the need for additional procedures at the time of medial patellofemoral ligament reconstruction<sup>32,34,38,43</sup>. As a result, the indications for medial patellofemoral ligament reconstruction remain controversial and further randomized prospective studies are needed for a consensus statement. It is the opinion of the senior author that medial patellofemoral ligament reconstruction is a

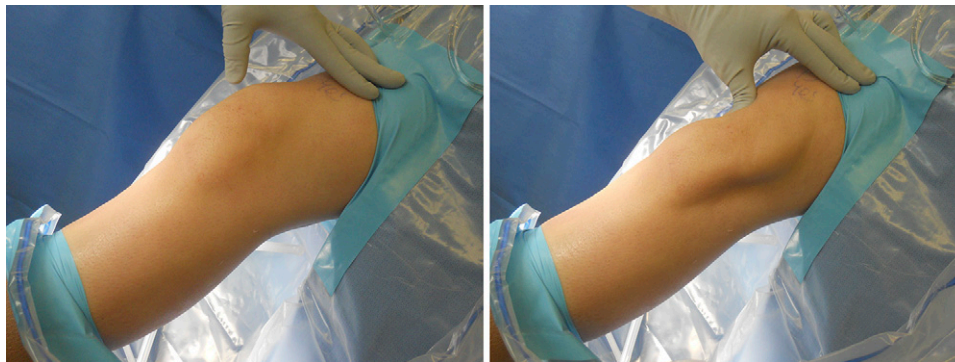


Fig. 2

Photographs made during an assessment of the patella with the patient under anesthesia. The application of a lateral force to the patella (right) identifies a lack of medial restraint, leading to patellar instability.

very successful procedure for the treatment of recurrent patellar instability. However, in cases of high-grade trochlear dysplasia or when the tibial tubercle-trochlear groove distance is  $>20$  mm, additional soft-tissue and osseous procedures are recommended along with medial patellofemoral ligament reconstruction in order to maximize long-term clinical outcomes while decreasing the strain on the medial patellofemoral ligament. Latt et al. described the first validated cadaveric model of trochlear dysplasia to help to define treatment algorithms for patellofemoral instability<sup>44</sup>.

#### Senior Author's Preferred Treatment

Medial patellofemoral ligament reconstruction involves a tendon transfer or a free graft. The graft can be a hamstring autograft or allograft involving the gracilis, semitendinosus, and/or quadriceps tendons. Risks associated with autograft harvest include pain, infection, and numbness in the distribution of the saphenous nerve during the graft harvest. The literature has yet to provide scientific support for the use of one choice over another.

#### Medial Patellofemoral Ligament Reconstruction with Semitendinosus Autograft (Surgical Technique)

The patient is positioned supine on a standard operating table. An examination is performed with the patient under

anesthesia to confirm patellar instability and to assess any other ligamentous damage (Fig. 2). A tourniquet is then placed on the proximal part of the thigh. Diagnostic arthroscopy is then performed, with care being taken to note the articulation between the patella and the trochlea (Fig. 3)—specifically, the trochlear morphology and the ability to displace the patella laterally. Often, a superolateral or superomedial outflow portal may be used for visualization to assess the relationship between the patella and trochlea with a 70° lens in addition to the standard 30° lens.

Next, the semitendinosus is harvested; however, an allograft also can be used as the graft choice. The pes anserine is palpated, and a 1 to 2-cm vertical or oblique skin incision is made 3 cm distal to the medial joint line and 2 cm medial to the tibial tuberosity. The dissection is carried down through the soft tissue and the sartorius fascia until the semitendinosus is visualized distal to the gracilis tendon. The semitendinosus tendon is then bluntly dissected with use of a right-angle clamp. Once clearly identified, the semitendinosus tendon is sharply released from its insertion on the tibia. A whipstitch with number-2 suture is attached to secure the tendon. Sharp dissection is used to release any fascial attachments at the inferior aspect of the semitendinosus tendon. The tendon may be translated into the surgical field to ensure that no attachments are remaining along the course of the tendon. A closed tendon stripper is then

used to release the tendon proximally.

The wound is irrigated thoroughly and is closed according to the preference of the individual surgeon. Meanwhile, the graft is prepared on the back table. The graft is sized to 180 mm in length and then is folded in half. Once double-bundled, the graft is generally  $90 \times 5$  or 6 mm in diameter.

Next, attention is turned to the patella. A 5-cm vertical skin incision is made along the midpoint of the medial aspect of the upper one-third of the patella and the medial epicondyle. The incision continues through the first layer to identify the medial aspect of the patella and the landmarks of the femoral attachment (the medial epicondyle and adductor tubercle). Care should be taken to avoid injury to the saphenous nerve during the approach. One may use the adductor magnus tendon insertion intraoperatively to find the saddle anterior and distal in relation to the medial epicondyle.

The graft is first anchored to the patella with use of a 3.5-mm suture anchor at the superior pole initially and another 3.5-mm anchor at the equator of the patella. A fascial plane is then created with a heavy hemostat deep to the subcutaneous soft tissue, extending medially and dorsally through the superficial and intermediate layers. The capsule (layer 3) is left intact, with the plane being kept extrasynovial to avoid graft abrasion and to facilitate complete healing. The looped end of the graft is passed through the extrasynovial tunnel

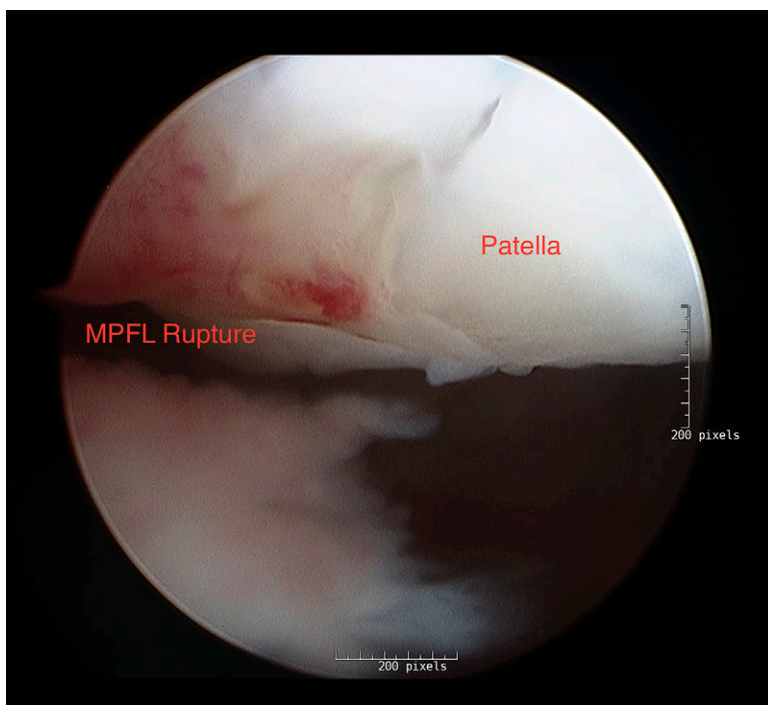


Fig. 3  
Arthroscopic image showing the articulation between the patella and the trochlea. MPFL = medial patellofemoral ligament.

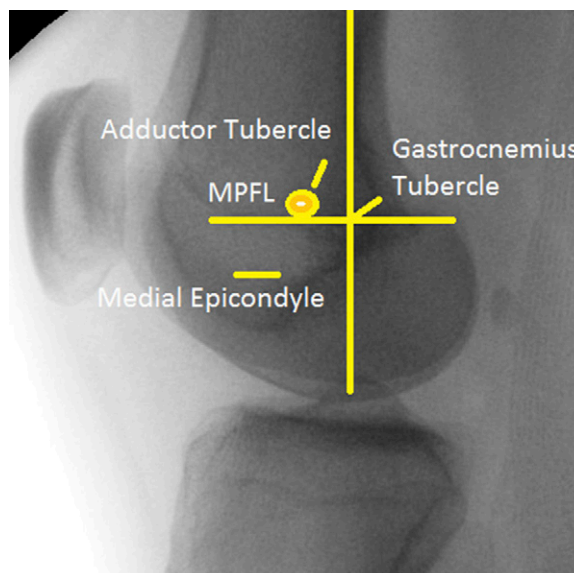
to the femoral insertion site by means of a Fiberwire suture (Arthrex, Naples, Florida) tied around the looped graft.

A lateral fluoroscopic image of the knee is made and a radiopaque instrument is used to identify the Schöttle point, the anatomic isometric insertion of the medial patellofemoral ligament (Fig. 4). The Schöttle point is determined on the lateral view by a line extending from the posterior cortex and

another perpendicular to the first, just proximal to the posterior-most point of the Blumensaat line. The Schöttle point is 1 mm anterosuperior to the intersection of these two lines<sup>45</sup>. Schöttle et al. described a radiographic technique to ensure accurate placement of the femoral tunnel with the use of a guide pin (Fig. 5)<sup>46</sup>. Servien et al. described a tunnel placement tangent to the posterior condyle and to a perpendicular line

at the posterior-most aspect of the Blumensaat line with a zone of 7 mm<sup>47</sup>. Steensen et al. found femoral tunnel placement to be crucial for establishing isometry of the medial patellofemoral ligament and reported that the femoral tunnel should be located at an anatomic point  $6.2 \pm 1.5$  mm distal to the adductor tubercle and  $13.3 \pm 2.4$  mm proximal to the medial femoral epicondyle<sup>17</sup>. Servien et al. and Elias and

Fig. 4  
Lateral fluoroscopic image identifying relevant anatomy of the distal part of the femur. MPFL = medial patellofemoral ligament.



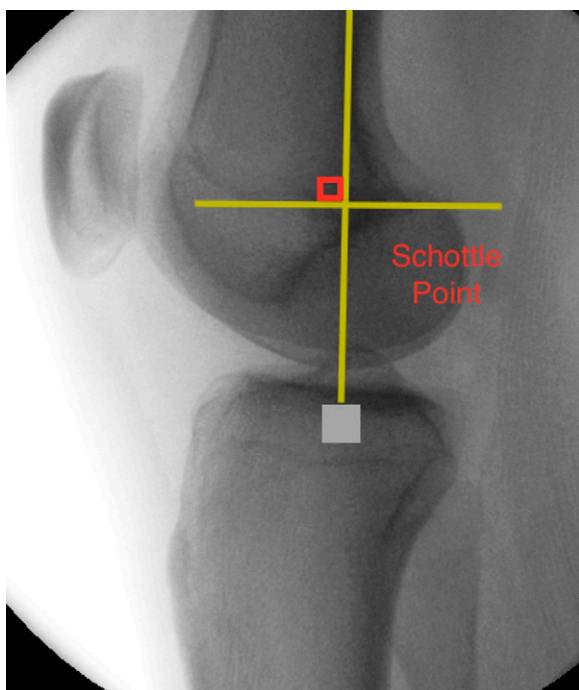


Fig. 5

Fluoroscopic image identifying the Schöttle point. The Schöttle point is determined on the lateral view by a line extending from the posterior cortex and another perpendicular to the first, just proximal to the posterior most point of Blumensaat line. The Schöttle point is 1 mm anterosuperior to the intersection of these two lines<sup>45</sup>.

Cosgarea described the challenges associated with reestablishing the anatomic femoral tunnel, noting that failure to do so can lead to increased medial tilt and medial-side patellofemoral contact pressures, possibly resulting in patellofemoral osteoarthritis over the long term<sup>47,48</sup>. Therefore, a Beath pin is then inserted into the femur after confirmation of placement with fluoroscopy. A cannulated reamer size-matched to the autograft is then used to ream a minimum distance of 60 mm into the femur to allow for adequate graft tensioning.

The knee is placed in 30° of flexion, and the guide pin for the interference screw is placed into the femoral tunnel, replacing the Beath pin. The graft is then passed through the femur with the passing stitch. Anatomic dangers include the neurovascular bundle of the adductor hiatus, the saphenous nerve, and/or the saphenous branch of the descending genicular artery<sup>49</sup>. Slack in the graft should be removed at 30° of flexion to ensure that the graft is isometric from extension to flexion. The native medial patellofemoral ligament tightens in extension and loosens following 30° to 40° of flexion; therefore, restoration of the native anatomy is

critical for a successful outcome. The degree of flexion during fixation has varied in the literature, with a systematic review showing values both below and above 60° of flexion, without a definitive conclusion<sup>50,51</sup>. Because biomechanical studies have shown that the medial patellofemoral ligament has maximum restraint in 30° of flexion, our fixation is tensioned and fixed in 30° of flexion<sup>6,52,53</sup>. Multiple methods have been reported for the fixation of the femoral portion of the medial patellofemoral ligament. Nomura et al. used staple fixation on the femoral side and reported that twenty-six of twenty-seven knees had an excellent or good result according to the Crosby and Insall grading system after a mean duration of follow-up of 5.2 years<sup>54</sup>. The use of a spiked washer on the femur was described in twelve patients, with no recurrent dislocation, subluxations, or positive apprehension sign at a minimum of three years of follow-up. Ellera Gomes et al. assessed sixteen knees after more than five years of follow-up and noted normal patellar tracking, a negative apprehension test, and an absence of patellar instability following medial patellofemoral reconstruction with semitendinosus autograft for the treatment of chronic instability<sup>55</sup>.

In our technique, the knee joint and the graft are preconditioned through multiple full cycles of motion with moderate tension on the graft to allow for resolution of positional laxity and also to dissipate some level of creep that may be present in the graft. Then, while mild tension at 30° is applied to the graft, a matched-fit interference screw is inserted into the femur until it has been countersunk by several millimeters. If a transfemoral sheath is used, attention to the peroneal nerve is critical. Evaluation of the patella is then completed. The arthroscope is then inserted back into the knee, and patellar tracking is observed. Similarly, the extra-articular tracking and laxity of the patella are evaluated through the range of motion of the knee. If any adjustments need to be made, the femoral screw is backed out, any tension or positioning adjustments are made, and the screw is reinserted.

The incisions are copiously irrigated with normal saline solution. The subcutaneous tissue is closed according to the preference of the individual surgeon. A sterile dressing is applied, and the patient is managed with a knee immobilizer. The patient can resume

weight-bearing as tolerated and has unrestricted range of motion.

Of particular importance is neuromuscular reeducation of the quadriceps as this muscle group has shown considerable weakness and activation deficits following knee surgery<sup>56</sup>. In addition, good quadriceps control is required for normal gait and optimum patellofemoral arthrokinematics<sup>57,58</sup>. Return to sport is based on a report of no pain, no instability, full strength with manual muscle testing, and excellent mechanics during a single-limb squat. In addition, the patient performs single limb hop tests, consisting of a single limb hop for distance, a triple limb hop for distance, a single limb hop for time, and a crossover hop for distance. The limb symmetry index must be  $\geq 90\%$ , and hop mechanics must be excellent as qualitatively assessed by the physical therapist.

### Complications

In a recent meta-analysis, Shah et al. reported a 26.1% complication rate in association with 629 medial patellofemoral ligament reconstructions<sup>51</sup>. The complications included patellar fracture, failure of the reconstruction and redislocation, loss of knee flexion, wound complications, and continued pain. Brennan et al.<sup>59</sup>, Christiansen et al.<sup>60</sup>, Ellera Gomes et al.<sup>55</sup>, and Lippacher et al.<sup>61</sup> all described iatrogenic patellar fractures with the anterior cortex of the patella being breached. Parikh and Wall<sup>12</sup> classified the fracture pattern into three types with corresponding treatments. Type-1 fractures, which are transverse fractures that are associated with the creation of the anterior patellar tunnel or drill-hole, are treated with the tension-band technique. Posterior placement is prevented by palpation of the articular surface and fluoroscopic imaging. Type-2 fractures, which are superior pole fractures that are associated with a lateral release and excessive dissection near the superior pole of the patella, are treated as a quadriceps tendon rupture<sup>59</sup>. Type-3 fractures are medial rim avulsion fractures through

the drill-holes, leading to lateral patellar instability<sup>12</sup>. Fithian et al. and Thaanat and Erasmus reported revision surgery to repair the graft to the patella after a medial rim fracture<sup>1,62</sup>. Finally, Steiner et al. described a fracture of the adductor tubercle at the femoral tunnel for the medial patellofemoral ligament graft<sup>34</sup>.

Recurrent lateral instability is generally caused by malpositioning of the femoral attachment and overtensioning or undertensioning of the graft. Positioning the femoral tunnel too anteriorly with the graft tensioned in flexion can lead to a loose graft. Conversely, the graft can fail secondary to increased strain following overtightening<sup>63</sup>. If the femoral tunnel is placed too distally or posteriorly, the graft will be tight in extension, leading to pain with extension that can manifest as an extensor lag. Furthermore, overtensioning of the graft can cause increased contact pressures on the medial patellar facet as well as medial patellar subluxation. Beck et al. noted that 2 N of tension is ideal for restoring patellofemoral biomechanics and allows the patella to center in the trochlear groove<sup>64</sup>. Overtensioning of the medial patellofemoral ligament has been implicated as a cause of stiffness. Thaanat and Erasmus reported two cases of pain and stiffness in association with overtightened medial patellofemoral ligament reconstructions<sup>65</sup>.

In a recent systematic review, loss of motion was found to be the second-most-reported complication (representing 13.4% of all complications) following recurrent instability related to graft loosening, rupture, and/or recurrent patellar instability (representing 32% of all complications)<sup>51</sup>. Over half of the patients underwent manipulation under anesthesia because of loss of knee flexion. In that study, the greatest number of secondary procedures were related to manipulation under anesthesia (reported in 1.4% of 629 knees)<sup>51</sup>. The native medial patellofemoral ligament is not under tension during the normal arc of motion. Christiansen et al., in a series of forty-four patients who underwent reconstruction of the medial patellofemoral

ligament with use of a gracilis tendon autograft and transverse patellar drill-holes, reported that four patients had a loss of flexion of  $>10^\circ$  and one patient underwent manipulation under anesthesia because of flexion of  $<90^\circ$ <sup>60</sup>. To improve motion, Parikh et al. suggested a postoperative protocol similar to anterior cruciate ligament (ACL) protocols<sup>11</sup>. The goal is to achieve  $0^\circ$  to  $90^\circ$  of motion by the end of the third week and  $0^\circ$  to  $120^\circ$  by the end of the sixth week. The authors recommended early manipulation with the patient under anesthesia to prevent arthrofibrosis if these goals are not met.

Wound complications are rare but have been successfully treated with irrigation and debridement in the majority of the cases<sup>34,60,66</sup>. To our knowledge, no cases of joint infections or deep-tissue infections have been reported in conjunction with medial patellofemoral ligament reconstruction<sup>63</sup>.

Finally, persistent pain resulting from prominent hardware has been reported<sup>34,60,66</sup>. Nomura et al. reported pain at the femoral fixation site in 57% and 23% of their patients who had been managed with staples and an integrated double-staple system, respectively<sup>66</sup>. Christiansen et al. removed interference screws at the femoral insertion site in three of forty-four patients<sup>60</sup>. In the largest systematic review to date, Shah et al. reported removal of symptomatic hardware in seven of 629 knees<sup>51</sup>.

Overall, it is difficult to draw definitive conclusions regarding the reported complications in the literature because of the heterogeneity of reconstruction techniques and the lack of standard reporting outcomes. Therefore, the surgeon must have great understanding of the anatomy and technical details of tunnel placement, graft fixation, and graft tensioning. Because of the lack of high-level studies and the array of fixation methods, it is difficult to isolate a sole reason for the high complication rates.

### Overview

Recurrent patellar instability continues to be a challenging problem for surgeons

as more patients are being diagnosed and managed each year. With the majority of complications being secondary to technical error, it is imperative for the surgeon to have a thorough understanding of the anatomy and biomechanics of the medial patellofemoral ligament. Furthermore, a combination of soft-tissue and osseous abnormalities contributes to the pathological process. As a result, the indications and algorithm for treatment continue to evolve. The ultimate goal for recurrent patellar instability should be to restore the native biomechanics and stability of the patellofemoral joint. The achievement of this goal may require a medial patellofemoral ligament reconstruction alone or in conjunction with additional soft-tissue and osseous procedures. Presently, evidence does not exist to support one surgical technique over another<sup>68-70</sup>.

#### Source of Funding

No external funds were received in support of this study.

Nirav H. Amin, MD<sup>1</sup>,  
T. Sean Lynch, MD<sup>1</sup>,  
Ronak M. Patel, MD<sup>1</sup>,  
Nimit Patel, MD<sup>2</sup>,  
Paul Saluan, MD<sup>1</sup>

<sup>1</sup>Department of Orthopaedic Surgery,  
Cleveland Clinic,  
5555 Transportation Boulevard,  
Cleveland, OH 44125

<sup>2</sup>Department of Orthopaedic Surgery,  
Drexel University College of Medicine,  
University Orthopaedic Institute,  
245 N. 15th Street, MS 420,  
Philadelphia, PA 19102

E-mail address for P. Saluan:  
SALUANP@ccf.org

#### References

1. Fithian DC, Paxton EW, Stone ML, Silva P, Davis DK, Elias DA, White LM. Epidemiology and natural history of acute patellar dislocation. *Am J Sports Med.* 2004 Jul-Aug;32(5):1114-21. Epub 2004 May 18.
2. Quirbach S, Smekal V, Rosenberger RE, El Attal R, Schöttle PB. [Anatomical double-bundle reconstruction of the medial patellofemoral ligament with a gracilis autograft]. [German]. *Oper Orthop Traumatol.* 2012 Apr;24(2):131-9.
3. Atkin DM, Fithian DC, Marangi KS, Stone ML, Dobson BE, Mendelsohn C. Characteristics of

patients with primary acute lateral patellar dislocation and their recovery within the first 6 months of injury. *Am J Sports Med.* 2000 Jul-Aug;28(4):472-9.

4. Conlan T, Garth WP Jr, Lemons JE. Evaluation of the medial soft-tissue restraints of the extensor mechanism of the knee. *J Bone Joint Surg Am.* 1993 May;75(5):682-93.

5. Tom A, Fulkerson JP. Restoration of native medial patellofemoral ligament support after patella dislocation. *Sports Med Arthrosc.* 2007 Jun;15(2):68-71.

6. Amis AA, Firer P, Mountney J, Senavongse W, Thomas NP. Anatomy and biomechanics of the medial patellofemoral ligament. *Knee.* 2003 Sep;10(3):215-20.

7. Nomura E, Horiuchi Y, Kihara M. Medial patellofemoral ligament restraint in lateral patellar translation and reconstruction. *Knee.* 2000 Apr 1;7(2):121-7.

8. Nomura E, Horiuchi Y, Inoue M. Correlation of MR imaging findings and open exploration of medial patellofemoral ligament injuries in acute patellar dislocations. *Knee.* 2002 May;9(2):139-43.

9. Sillanpää PJ, Mäenpää HM, Mattila VM, Visuri T, Pihlajamäki H. Arthroscopic surgery for primary traumatic patellar dislocation: a prospective, nonrandomized study comparing patients treated with and without acute arthroscopic stabilization with a median 7-year follow-up. *Am J Sports Med.* 2008 Dec;36(12):2301-9. Epub 2008 Sep 1.

10. Elias DA, White LM, Fithian DC. Acute lateral patellar dislocation at MR imaging: injury patterns of medial patellar soft-tissue restraints and osteochondral injuries of the inferomedial patella. *Radiology.* 2002 Dec;225(3):736-43.

11. Parikh SN, Nathan ST, Wall EJ, Eismann EA. Complications of medial patellofemoral ligament reconstruction in young patients. *Am J Sports Med.* 2013 May;41(5):1030-8. Epub 2013 Mar 28.

12. Parikh SN, Wall EJ. Patellar fracture after medial patellofemoral ligament surgery: a report of five cases. *J Bone Joint Surg Am.* 2011 Sep 7;93(17):e97-1-8.

13. Arendt EA, Moeller A, Age J. Clinical outcomes of medial patellofemoral ligament repair in recurrent (chronic) lateral patella dislocations. *Knee Surg Sports Traumatol Arthrosc.* 2011 Nov;19(11):1909-14. Epub 2011 Apr 30.

14. Warren LF, Marshall JL. The supporting structures and layers on the medial side of the knee: an anatomical analysis. *J Bone Joint Surg Am.* 1979 Jan;61(1):56-62.

15. Nomura E, Inoue M, Osada N. Anatomical analysis of the medial patellofemoral ligament of the knee, especially the femoral attachment. *Knee Surg Sports Traumatol Arthrosc.* 2005 Oct;13(7):510-5. Epub 2005 May 13.

16. LaPrade RF, Engebretsen AH, Ly TV, Johansen S, Wentorf FA, Engebretsen L. The anatomy of the medial part of the knee. *J Bone Joint Surg Am.* 2007 Sep;89(9):2000-10.

17. Steensen RN, Dopirak RM, McDonald WG 3rd. The anatomy and isometry of the medial patellofemoral ligament: implications for reconstruction. *Am J Sports Med.* 2004 Sep;32(6):1509-13. Epub 2004 Jul 20.

18. Bicos J, Fulkerson JP, Amis A. Current concepts review: the medial patellofemoral ligament. *Am J Sports Med.* 2007 Mar;35(3):484-92.

19. Ahmad CS, McCarthy M, Gomez JA, Shubin Stein BE. The moving patellar apprehension test for lateral patellar instability. *Am J Sports Med.* 2009 Apr;37(4):791-6. Epub 2009 Feb 3.

20. Senavongse W, Amis AA. The effects of articular, retinacular, or muscular deficiencies on patellofemoral joint stability: a biomechanical study in vitro. *J Bone Joint Surg Br.* 2005 Apr;87(4):577-82.

21. Palmu S, Kallio PE, Donell ST, Helenius I, Nietosvaara Y. Acute patellar dislocation in children and adolescents: a randomized clinical trial. *J Bone Joint Surg Am.* 2008 Mar;90(3):463-70.

22. Hennrikus W, Pylawka T. Patellofemoral instability in skeletally immature athletes. *Instr Course Lect.* 2013;62:445-53.

23. Arendt EA, Fithian DC, Cohen E. Current concepts of lateral patella dislocation. *Clin Sports Med.* 2002 Jul;21(3):499-519.

24. Macnab I. Recurrent dislocation of the patella. *J Bone Joint Surg Am.* 1952 Oct;34(4):957-67 passim.

25. Hawkins RJ, Bell RH, Anisette G. Acute patellar dislocations. The natural history. *Am J Sports Med.* 1986 Mar-Apr;14(2):117-20.

26. Cofield RH, Bryan RS. Acute dislocation of the patella: results of conservative treatment. *J Trauma.* 1977 Jul;17(7):526-31.

27. Stefancin JJ, Parker RD. First-time traumatic patellar dislocation: a systematic review. *Clin Orthop Relat Res.* 2007 Feb;455:93-101.

28. Colvin AC, West RV. Patellar instability. *J Bone Joint Surg Am.* 2008 Dec;90(12):2751-62.

29. Sillanpää PJ, Mattila VM, Mäenpää H, Kiuru M, Visuri T, Pihlajamäki H. Treatment with and without initial stabilizing surgery for primary traumatic patellar dislocation. A prospective randomized study. *J Bone Joint Surg Am.* 2009 Feb;91(2):263-73.

30. Fulkerson JP, Shea KP. Disorders of patellofemoral alignment. *J Bone Joint Surg Am.* 1990 Oct;72(9):1424-9.

31. Dejour H, Walch G, Nove-Josserand L, Guier C. Factors of patellar instability: an anatomical radiographic study. *Knee Surg Sports Traumatol Arthrosc.* 1994;2(1):19-26.

32. Wagner D, Pflazer F, Hingelbaum S, Huth J, Mauch F, Bauer G. The influence of risk factors on clinical outcomes following anatomical medial patellofemoral ligament (MPFL) reconstruction using the gracilis tendon. *Knee Surg Sports Traumatol Arthrosc.* 2013 Feb;21(2):318-24. Epub 2012 Apr 27.

33. Bollier M, Fulkerson JP. The role of trochlear dysplasia in patellofemoral instability. *J Am Acad Orthop Surg.* 2011 Jan;19(1):8-16.

34. Steiner TM, Torga-Spak R, Teitge RA. Medial patellofemoral ligament reconstruction in patients with lateral patellar instability and trochlear dysplasia. *Am J Sports Med.* 2006 Aug;34(8):1254-61. Epub 2006 Mar 27.

35. Nelitz M, Williams RS, Lippacher S, Reichel H, Dornacher D. Analysis of failure and clinical outcome after unsuccessful medial patellofemoral ligament reconstruction in young patients. *Int Orthop.* 2014 Nov;38(11):2265-72. Epub 2014 Jul 20.

36. Banke IJ, Kohn LM, Meidinger G, Otto A, Hensler D, Beitzel K, Imhoff AB, Schöttle PB. Combined trochleoplasty and MPFL reconstruction for treatment of chronic patellofemoral instability: a prospective minimum 2-year



- follow-up study. *Knee Surg Sports Traumatol Arthrosc.* 2014 Nov;22(11):2591-8. Epub 2013 Jul 14.
- 37.** Koh JL, Stewart C. Patellar instability. *Clin Sports Med.* 2014 Jul;33(3):461-76. Epub 2014 May 29.
- 38.** Fucentese SF, Zingg PO, Schmitt J, Pfirrmann CW, Meyer DC, Koch PP. Classification of trochlear dysplasia as predictor of clinical outcome after trochleoplasty. *Knee Surg Sports Traumatol Arthrosc.* 2011 Oct;19(10):1655-61. Epub 2011 Feb 8.
- 39.** Schöttle PB, Fucentese SF, Pfirrmann C, Bereiter H, Romero J. Trochleoplasty for patellar instability due to trochlear dysplasia: a minimum 2-year clinical and radiological follow-up of 19 knees. *Acta Orthop.* 2005 Oct;76(5):693-8.
- 40.** Schöttle PB, Fucentese SF, Romero J. Clinical and radiological outcome of medial patellofemoral ligament reconstruction with a semitendinosus autograft for patella instability. *Knee Surg Sports Traumatol Arthrosc.* 2005 Oct;13(7):516-21. Epub 2005 Jun 15.
- 41.** Balcarek P, Jung K, Ammon J, Walde TA, Frosch S, Schüttrumpf JP, Stürmer KM, Frosch KH. Anatomy of lateral patellar instability: trochlear dysplasia and tibial tubercle-trochlear groove distance is more pronounced in women who dislocate the patella. *Am J Sports Med.* 2010 Nov;38(11):2320-7. Epub 2010 Aug 16.
- 42.** Matsushita T, Kuroda R, Oka S, Matsumoto T, Takayama K, Kurosaka M. Clinical outcomes of medial patellofemoral ligament reconstruction in patients with an increased tibial tuberosity-trochlear groove distance. *Knee Surg Sports Traumatol Arthrosc.* 2014 Oct;22(10):2438-44. Epub 2014 Mar 4.
- 43.** Hopper GP, Leach WJ, Rooney BP, Walker CR, Blyth MJ. Does degree of trochlear dysplasia and position of femoral tunnel influence outcome after medial patellofemoral ligament reconstruction? *Am J Sports Med.* 2014 Mar;42(3):716-22. Epub 2014 Jan 23.
- 44.** Latt LD, Christopher M, Nicolini A, Burk DR, Dezfuli B, Serack BJ, Fithian DC. A validated cadaveric model of trochlear dysplasia. *Knee Surg Sports Traumatol Arthrosc.* 2014 Oct;22(10):2357-63. Epub 2014 May 8.
- 45.** Schöttle PB, Schmeling A, Rosenstiel N, Weiler A. Radiographic landmarks for femoral tunnel placement in medial patellofemoral ligament reconstruction. *Am J Sports Med.* 2007 May;35(5):801-4. Epub 2007 Jan 31.
- 46.** Schöttle P, Schmeling A, Romero J, Weiler A. Anatomical reconstruction of the medial patellofemoral ligament using a free gracilis autograft. *Arch Orthop Trauma Surg.* 2009 Mar;129(3):305-9. Epub 2008 Aug 15.
- 47.** Servien E, Fritsch B, Lustig S, Demey G, Debarge R, Lapra C, Neyret P. In vivo positioning analysis of medial patellofemoral ligament reconstruction. *Am J Sports Med.* 2011 Jan;39(1):134-9. Epub 2010 Oct 7.
- 48.** Elias JJ, Cosgarea AJ. Technical errors during medial patellofemoral ligament reconstruction could overload medial patellofemoral cartilage: a computational analysis. *Am J Sports Med.* 2006 Sep;34(9):1478-85. Epub 2006 May 9.
- 49.** Jacobi M, Reischl N, Bergmann M, Bouaicha S, Djonov V, Magnussen RA. Reconstruction of the medial patellofemoral ligament using the adductor magnus tendon: an anatomic study. *Arthroscopy.* 2012 Jan;28(1):105-9. Epub 2011 Oct 15.
- 50.** Fink C, Veselko M, Herbolt M, Hoser C. Minimally invasive reconstruction of the medial patellofemoral ligament using quadriceps tendon. *Arthrosc Tech.* 2014 Jun;3(3):e325-9. Epub 2014 May 12.
- 51.** Shah JN, Howard JS, Flanigan DC, Brophy RH, Carey JL, Lattermann C. A systematic review of complications and failures associated with medial patellofemoral ligament reconstruction for recurrent patellar dislocation. *Am J Sports Med.* 2012 Aug;40(8):1916-23. Epub 2012 Jun 7.
- 52.** Davis DK, Fithian DC. Techniques of medial retinacular repair and reconstruction. *Clin Orthop Relat Res.* 2002 Sep;402:38-52.
- 53.** Li J, Li Y, Wei J, Wang J, Gao S, Shen Y. A simple technique for reconstruction of medial patellofemoral ligament with bone-fascia tunnel fixation at the medial margin of the patella: a 6-year-minimum follow-up study. *J Orthop Surg Res.* 2014;9:66. Epub 2014 Aug 15.
- 54.** Nomura E, Horiuchi Y, Kihara M. A mid-term follow-up of medial patellofemoral ligament reconstruction using an artificial ligament for recurrent patellar dislocation. *Knee.* 2000 Dec 1;7(4):211-5.
- 55.** Ellera Gomes JL, Stigler Marczyk LR, César de César P, Jungblut CF. Medial patellofemoral ligament reconstruction with semitendinosus autograft for chronic patellar instability: a follow-up study. *Arthroscopy.* 2004 Feb;20(2):147-51.
- 56.** Glatthorn JF, Berendts AM, Bizzini M, Munzinger U, Maffiuletti NA. Neuromuscular function after arthroscopic partial meniscectomy. *Clin Orthop Relat Res.* 2010 May;468(5):1336-43. Epub 2009 Nov 21.
- 57.** Palmieri-Smith RM, Thomas AC, Wojtys EM. Maximizing quadriceps strength after ACL reconstruction. *Clin Sports Med.* 2008 Jul;27(3):405-24. vii-ix.
- 58.** Powers CM, Ward SR, Fredericson M, Guillet M, Shellock FG. Patellofemoral kinematics during weight-bearing and non-weight-bearing knee extension in persons with lateral subluxation of the patella: a preliminary study. *J Orthop Sports Phys Ther.* 2003 Nov;33(11):677-85.
- 59.** Brennan SA, Walls R, Jackson M, Moran R. Superior pole sleeve fracture following patellar stabilisation. *Knee.* 2009 Jun;16(3):235-7. Epub 2008 Dec 17.
- 60.** Christiansen SE, Jacobsen BW, Lund B, Lind M. Reconstruction of the medial patellofemoral ligament with gracilis tendon autograft in transverse patellar drill holes. *Arthroscopy.* 2008 Jan;24(1):82-7. Epub 2007 Nov 5.
- 61.** Lippacher S, Reichel H, Nelitz M. [Patellar fracture after patellar stabilization]. [German]. *Orthopade.* 2010 May;39(5):516-8.
- 62.** Thunat M, Erasmus PJ. Recurrent patellar dislocation after medial patellofemoral ligament reconstruction. *Knee Surg Sports Traumatol Arthrosc.* 2008 Jan;16(1):40-3. Epub 2007 Nov 1.
- 63.** Tanaka MJ, Bollier MJ, Andrich JT, Fulkerson JP, Cosgarea AJ. Complications of medial patellofemoral ligament reconstruction: common technical errors and factors for success: AAOS exhibit selection. *J Bone Joint Surg Am.* 2012 Jun 20;94(12):e87.
- 64.** Beck P, Brown NA, Greis PE, Burks RT. Patellofemoral contact pressures and lateral patellar translation after medial patellofemoral ligament reconstruction. *Am J Sports Med.* 2007 Sep;35(9):1557-63. Epub 2007 Apr 13.
- 65.** Thunat M, Erasmus PJ. Management of overtight medial patellofemoral ligament reconstruction. *Knee Surg Sports Traumatol Arthrosc.* 2009 May;17(5):480-3. Epub 2009 Jan 9.
- 66.** Nomura E, Inoue M, Kobayashi S. Long-term follow-up and knee osteoarthritis change after medial patellofemoral ligament reconstruction for recurrent patellar dislocation. *Am J Sports Med.* 2007 Nov;35(11):1851-8. Epub 2007 Aug 27.
- 67.** Drez D Jr, Edwards TB, Williams CS. Results of medial patellofemoral ligament reconstruction in the treatment of patellar dislocation. *Arthroscopy.* 2001 Mar;17(3):298-306.
- 68.** Ma LF, Wang F, Chen BC, Wang CH, Zhou JW, Wang HY. Medial retinaculum plasty versus medial patellofemoral ligament reconstruction for recurrent patellar instability in adults: a randomized controlled trial. *Arthroscopy.* 2013 May;29(5):891-7. Epub 2013 Apr 6.
- 69.** Buckens CF, Saris DB. Reconstruction of the medial patellofemoral ligament for treatment of patellofemoral instability: a systematic review. *Am J Sports Med.* 2010 Jan;38(1):181-8. Epub 2009 Dec 4.
- 70.** Wylie JD, Burks RT. Medial patellofemoral ligament reconstruction with semitendinosus autograft. *Arthrosc Tech.* 2013;2(4):e417-21. Epub 2013 Oct 17.