

Clinical and Biomechanical Evaluation of an All-Arthroscopic Suprapectoral Biceps Tenodesis

Cynthia A. Kahlenberg,* BA, Ronak M. Patel,[†] MD, Rueben Nair,* MD, Prashant P. Deshmane,* MD, Galen Harnden,* MD, and Michael A. Terry,*[‡] MD

Investigation performed at Northwestern University Feinberg School of Medicine, Chicago, Illinois, USA

Background: Pathology of the long head of the biceps (LHB) is a well-recognized cause of shoulder pain in the adult population and can be managed surgically with tenotomy or tenodesis.

Purpose: To compare the biomechanical strength of an all-arthroscopic biceps tenodesis technique that places the LHB distal to the bicipital groove in the suprapectoral region with a more traditional mini-open subpectoral tenodesis. This study also evaluates the clinical outcomes of patients who underwent biceps tenodesis using the all-arthroscopic technique.

Study Design: Controlled laboratory study and case series; Level of evidence, 4.

Methods: For the biomechanical evaluation of the all-arthroscopic biceps tenodesis technique, in which the biceps tendon is secured to the suprapectoral region distal to the bicipital groove with an interference screw, 14 fresh-frozen human cadaveric shoulders (7 matched pairs) were used to compare load to failure and displacement at peak load with a traditional open subpectoral location. For the clinical evaluation, 49 consecutive patients (51 shoulders) with a mean follow-up of 2.4 years who underwent an all-arthroscopic biceps tenodesis were evaluated using the American Shoulder and Elbow Surgeons (ASES) score preoperatively and at last follow-up, as well as the University of California, Los Angeles (UCLA) Shoulder Score at last follow-up.

Results: On biomechanical evaluation, there was no significant difference in peak failure load, displacement at peak load, or displacement after cyclic testing between the arthroscopic suprapectoral and mini-open subpectoral groups. In the clinical evaluation, the mean preoperative ASES score was 65.4, compared with 87.1 at last follow-up. The mean UCLA score at last follow-up was 30.2. Forty-eight (94.1%) patients reported satisfaction with the surgery. In subgroup analysis comparing patients who had a rotator cuff repair or labral repair at time of tenodesis with patients who did not have either of these procedures, there were no significant differences in UCLA or ASES scores.

Conclusion: The excellent biomechanical strength as well as the high rate of satisfaction after surgery and high ASES and UCLA postoperative scores make this technique a novel option for treatment of biceps tendon pathology.

Keywords: arthroscopic; biceps tenodesis; biomechanical; clinical outcomes

Pathology of the long head of the biceps (LHB) is a recognized source of shoulder pain secondary to degeneration,

[‡]Address correspondence to Michael A. Terry, MD, Department of Orthopaedic Surgery, Northwestern University Feinberg School of Medicine, 676 N Saint Clair, Suite 1350, Chicago, IL 60611, USA (e-mail: m-terry@northwestern.edu).

*Department of Orthopaedic Surgery, Northwestern University Feinberg School of Medicine, Chicago, Illinois, USA.

[†]Illinois Bone and Joint Institute LLC, Chicago, Illinois, USA.

One or more of the authors has declared the following potential conflict of interest or source of funding: Supplies for biomechanical testing were received from Smith & Nephew. M.A.T. receives royalties and general research support from Smith & Nephew.

The Orthopaedic Journal of Sports Medicine, 2(10), 2325967114553558

DOI: 10.1177/2325967114553558

© The Author(s) 2014

inflammation, mechanical irritation, trauma, or sports-related injury.¹ In cases where conservative treatment fails, the decision between tenotomy versus tenodesis, as well as the optimal location of a tenodesis of the LHB, remains controversial.

Some authors have found no significant difference in outcomes between tenotomy and tenodesis.^{5,10,23} Biceps tenotomy has been recommended over tenodesis because it is a faster and technically less difficult procedure and may require less postoperative rehabilitation.¹⁰ A recent review found no functional difference between the outcomes of tenodesis versus tenotomy but did find a higher incidence of the cosmetic “popeye” deformity with tenotomy.³⁴ Furthermore, Boileau et al⁵ retrospectively reviewed 68 cases of massive rotator cuff tears that were also treated with tenotomy or tenodesis and found that 62% of patients

This open-access article is published and distributed under the Creative Commons Attribution - NonCommercial - No Derivatives License (<http://creativecommons.org/licenses/by-nc-nd/3.0/>), which permits the noncommercial use, distribution, and reproduction of the article in any medium, provided the original author and source are credited. You may not alter, transform, or build upon this article without the permission of the Author(s). For reprints and permission queries, please visit SAGE's Web site at <http://www.sagepub.com/journalsPermissions.nav>.

undergoing tenotomy had a popeye deformity. Similarly, Lim et al¹⁵ reported the popeye deformity in 45% of patients, as well as a cramp-like arm pain on exertion in 8% of patients undergoing biceps tenotomy. In addition to the popeye deformity and pain on exertion, tenotomy has been shown to result in loss of power in elbow flexion and supination of the forearm, as well as weakness with vigorous use of the biceps.^{4,7}

Biceps tenodesis is a popular alternative to tenotomy and can be performed either open or arthroscopically. Tenodesis is often the favored procedure in younger, thinner, or more active patients.^{1,12} Many techniques for arthroscopic tenodesis have been described,^{2,6,16,26,32} most of which place the tenodesis in the proximal bicipital groove. Disadvantages of this tenodesis site include a higher reported revision rate compared with a distal tenodesis, which places the tenodesis outside of the groove, typically in the subpectoral region.³¹ There is also a potential for postoperative pain from the groove with traditional arthroscopic tenodesis placement.^{21,28} Open and mini-open subpectoral techniques, which avoid the disadvantages associated with tenodesis in the bicipital groove, have also been described.^{20,28} However, these techniques are not performed arthroscopically and involve the risks and morbidity of a procedure with an open incision.

Lutton et al¹⁷ described a novel technique in which the biceps was tenodesed arthroscopically but distal to the bicipital groove in the suprapectoral region. In their series of 12 patients, all had improvement in clinical outcomes and were asymptomatic at final follow-up. Few studies are available for this relatively “new” technique. The purposes of this study were to assess biomechanical strength of arthroscopic distal suprapectoral biceps tenodesis in a cadaveric model compared with traditional open subpectoral biceps tenodesis and to investigate the clinical outcomes of 51 cases in which this technique was used.

METHODS

Surgical Technique

The specific arthroscopic suprapectoral tenodesis technique and site has been previously described by Lutton et al.¹⁷ Briefly, an additional anterior portal is made, and the plan for the length and location of the tenodesis is decided based on baseline anatomic landmarks that were previously described by Denard et al.⁹ The tenodesis site between the subscapularis and the pectoralis major is identified and prepared, and the biceps is secured with interference screw fixation (Figure 1).

Cadaveric Biomechanical Analysis

In the biomechanical evaluation, load to failure and displacement at peak load were assessed for a bony tenodesis using interference screw fixation for both an arthroscopic distal suprapectoral position and an open subpectoral location.

A total of 14 fresh-frozen human cadaveric shoulders (7 matched pairs) were used for this study. All specimens were thawed at room temperature before dissection, repair, and testing. Each shoulder was inspected at the glenohumeral

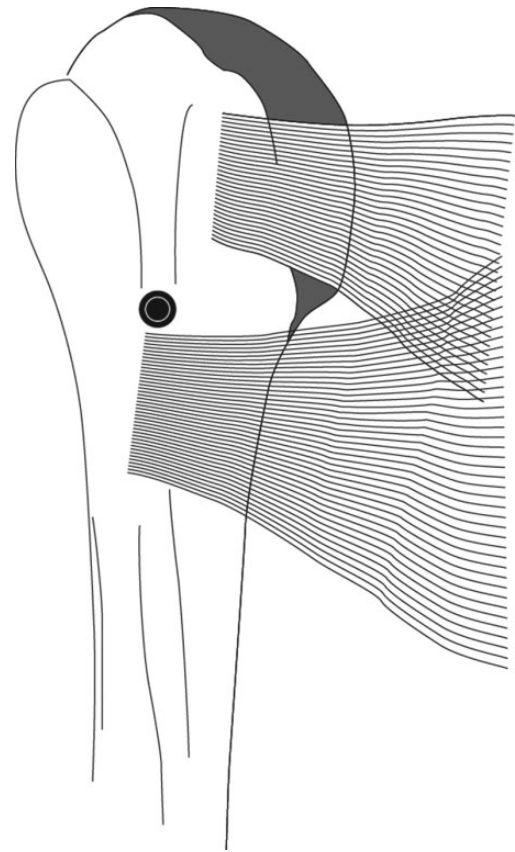


Figure 1. The long head of the biceps is placed distal to the bicipital groove in the suprapectoral region.

joint to exclude specimens with significant biceps pathology, including rupture, tear, fraying, and/or fracture of the humerus. The tendon width of each shoulder was assessed to ensure adequate size for interference screw fixation and analysis. A polyetheretherketone (PEEK) interference screw (Biceptor; Smith & Nephew) was used for the tenodesis in all cases.

Four female and 3 male donors with a mean age of 60 years (range, 47-75 years) provided 7 left and 7 right shoulders.

An a priori power analysis based on literature data showed that 7 specimens per group would provide 80% power to detect a significant difference in mean ultimate load to failure between the 2 groups (effect size, 0.6; $P = .05$). Each specimen from a matched pair was randomized to 1 of 2 surgical biceps tenodesis procedures: (1) arthroscopic suprapectoral tenodesis distal to the bicipital groove between the subscapularis and pectoralis major tendons or (2) mini-open subpectoral tenodesis at the inferior border of the pectoralis major tendon.

Surgical Technique

The surgical technique for group 1 (arthroscopic suprapectoral tenodesis) was as described above. However, that for group 2 (mini-open subpectoral tenodesis) was as follows:

The inferior border of the pectoralis major tendon was palpated. A 3-cm incision was then made on the medial aspect of the arm starting 1 cm proximal to the inferior aspect of the pectoralis major tendon. Dissection was taken down to the humerus with the aid of tenotomy scissors and electrocautery. The fascia overlying the LHB and pectoralis major tendon was opened, and the transverse fibers of the pectoralis major tendon were identified. A right angle was inserted deep to the pectoralis tendon to pull the LHB tendon out of the wound. A bony bed for fixation was created 1 cm proximal to the inferior border of the pectoralis tendon. The LHB tendon was then cut at the appropriate tension (~ 2 cm proximal to the musculotendinous junction).²⁸ A similar technique to drill and position the interference screw as previously mentioned was then performed. An 8×15 -mm PEEK interference screw was then advanced over the guide wire until flush with the anterior humeral cortex. The guide wire was removed, and the extraneous stump of the proximal LHB tendon was excised. The narrow distal intramedullary space limited screw length to 15 mm compared with the 25-mm screw used proximally.

Biomechanical Testing

The biomechanical analysis performed emulated a published and well-described protocol³³ and will be briefly restated. In all specimens, all soft tissue was removed from the humerus except the biceps tendon and muscle belly. Each proximal humerus–biceps tendon specimen was mounted in a materials testing system (MTS Insight 858; MTS Systems) (Figure 2). A custom dry ice soft tissue cryo-clamp was used to secure the biceps muscle-tendon unit to the test actuator and inline 500-N load cell. A custom “Christmas tree” fixture stabilized the humeral head to the base of the MTS. Pull was maintained in line and parallel to the humeral shaft approximating the *in vivo* biceps muscle/tendon force vector.

The following parameters were applied to each specimen individually: preload at constant 5 N for 2 minutes, cyclical loading for 500 cycles from 5 to 70 N at 1 Hz, return to 5-N load for 1 minute, pull-to-failure test at 1 mm/s.

All testing was performed at room temperature. The tendon graft was regularly moistened with a saline solution spray throughout testing to avoid desiccation. The distance between the screw and the cryo-clamp was initially set at approximately 50 mm for all the tests. Displacement baseline (re-zero displacement) was set after the initial 5-minute preload. Cyclical displacement was calculated as the peak actuator displacement of cycle 500 relative to baseline. Data computed from the failure test included ultimate load to failure, displacement at peak load, displacement after cycle 500, and method/location of graft failure.

Patients

After approval by the institutional review board, the medical records of 49 patients (51 shoulders) who underwent arthroscopic biceps tenodesis performed by the senior surgeon between May 2009 and February 2012 were identified




Figure 2. Fixture used for biomechanical evaluation.

by Current Procedural Terminology (CPT) filters. Each medical record was reviewed to ensure the operative procedure was an all-arthroscopic distal suprascapular bony biceps tenodesis. Patients were excluded if any part of their surgery was performed through an open incision rather than arthroscopically. A Biceptor PEEK interference screw specific for biceps tenodesis was used in all cases. All patients were evaluated preoperatively with plain radiographs, magnetic resonance imaging, and clinical examination.

Outcome scores were collected, including the American Shoulder and Elbow Surgeons (ASES) Standardized Shoulder Assessment Form³⁰ both preoperatively and at latest follow-up, as well as the University of California, Los Angeles (UCLA) Shoulder Rating Scale³ at latest follow-up. The ASES and the UCLA scores are commonly used outcome measures for arthroscopic shoulder surgery. The UCLA score is a postoperative score that incorporates patient satisfaction as part of the measurement. Operative reports and clinical notes were reviewed to assess for complications and details of each procedure.

The indications for biceps tenodesis included symptomatic partial ($\geq 25\%$) thickness tears of the LHB, subluxation of the LHB medially or with a tear of the subscapularis, type IV or symptomatic type II superior labrum anterior-posterior (SLAP) tears, failed SLAP repairs, chronic pain from LHB tendonitis, or symptomatic LHB tendonitis with an inflamed LHB seen on diagnostic arthroscopy.²¹

TABLE 1
Biomechanical Outcomes

Group ^a	Side	Age, y	Sex	Failure (Peak) Load, N	Displacement, mm		Failure Mode
					At Peak Load	At 500 Cycles	
1	Left	57	Male	143	10.35	8.31	Tendon pullout at screw
1	Left	54	Male	113	5.71	4.84	Tendon tear at tendon-screw junction
1	Right	47	Female	443	9.78	3.76	Tendon failed midtendon
1	Right	75	Female	189	34.80	10.11	Tendon tear at tendon-screw junction
1	Left	52	Female	151	8.56	6.58	Tendon tear at tendon-screw junction
1	Left	60	Male	288	18.25	13.32	Tendon failed midtendon
1	Right	75	Female	110	27.58	25.74	Tendon pullout at screw
2	Right	57	Male	Failed at cycle 191	—	—	Tendon tear at tendon-screw junction
2	Right	54	Male	N/A	—	—	
2	Left	75	Female	Failed at cycle 16	—	—	Tendon tear at tendon-screw junction
2	Right	52	Female	150	19.80	12.14	Tendon tear at tendon-screw junction
2	Left	47	Female	166	8.21	5.12	Tendon tear at tendon-screw junction
2	Left	75	Female	Failed at cycle 18	—	—	Tendon tear at tendon-screw junction
2	Right	60	Male	100	14.65	3.98	Tendon tear at tendon-screw junction

^aGroup 1, all-arthroscopic suprapectoral technique; group 2, mini-open subpectoral technique.

Postoperative Protocol

Patients who underwent biceps tenodesis without additional soft tissue repair or reconstruction wore a sling for comfort postoperatively and were instructed to discontinue use of the sling as tolerated. Passive range of motion exercises were started immediately after surgery. Active range of motion was initiated after 2 to 3 days, followed by resistance exercises at week 7, and weight training at week 8. The postoperative protocol was modified based on other procedures performed at the time of biceps tenodesis surgery. Patients undergoing rotator cuff repair or labral repair were immobilized for longer periods of time.

Patients were followed after surgery at weeks 2, 6, and 12 and at additional 3-month intervals as clinically necessary.

Statistical Analysis

Biomechanical outcomes were modeled on the log scale using linear mixed-effects modeling techniques, which account for repeated observations within a particular donor. Model parameter estimates and 95% confidence intervals were transformed back onto the original scale of the data using the antilogarithm. Therefore, the type of mean used was the geometric mean.

All analyses were performed using R software (v 3.0.1; www.r-project.org). A 5% significance level was used for all analyses.

RESULTS

Biomechanical Evaluation

One of the specimens was unable to be tested, as it failed in the process of mounting on the MTS platform.

Three of the remaining 6 shoulders in the mini-open subpectoral tenodesis group failed during cyclic loading

(cycles 16, 18, and 191). The failures in these 3 specimens consistently occurred as a tear at the tendon-screw junction. Failure during cyclic loading prevented subsequent testing of ultimate load to failure, stiffness, and displacement per study protocol.

Ten shoulders completed all aspects of biomechanical analysis. The results of all parameters in all specimens are shown in Table 1. There was no significant difference in peak failure load between the arthroscopic suprapectoral (group 1) and mini-open subpectoral tenodesis groups (group 2) ($P = .22$). Furthermore, there was no difference in displacement at peak load ($P = .38$) or after cyclic testing ($P = .58$).

Clinical Series

The clinical study group ($N = 49$ patients) included 26 men and 23 women with a mean age of 52.6 years (range, 16-77 years). Twenty-two patients had a right shoulder operation, 25 had a left shoulder operation, and 2 had a tenodesis performed on bilateral shoulders. The mean follow-up period was 2.4 years (range, 1.4-4.6 years).

None of the tenodesis procedures were converted to open procedures. All patients had at least 1 procedure performed at the time of surgery in addition to the tenodesis. These procedures included rotator cuff repair or debridement, labral repair or debridement, subacromial decompression, bursectomy, distal clavicle excision, and acromioplasty (Table 2). One patient (2.0%) had a visible popeye deformity at last follow-up. The patient reported that this deformity was cosmetically acceptable to him. There were no other surgical or postoperative complications reported in this cohort.

The mean preoperative ASES score was 64.5. At the latest follow-up, the mean ASES score was 87.1 and the mean UCLA score was 30.2 (Table 3). Thirty-three (64.4%) patients reported that their shoulder was pain free at last

TABLE 2

Surgical Procedures Performed in Addition to Tenodesis

Surgical Procedure	n (%)
Rotator cuff repair	22 (41.3)
Rotator cuff debridement	15 (29.4)
Labrum repair	6 (11.8)
Labrum debridement	41 (80.4)
Subacromial decompression	42 (82.4)
Bursectomy	29 (56.9)
Distal clavicle excision	16 (31.4)
Acromioplasty	9 (17.4)

TABLE 3
Outcome Scores^a

	Mean ± SD	Min	Median	Max	P
ASES score					
Preoperative	65.4 ± 9.8	31.7	68.3	78.3	<.0001
Postoperative	87.1 ± 15.6	41.7	93.3	100	
UCLA score					
Postoperative	30.2 ± 5.7	15	31	35	N/A

^aASES, American Shoulder and Elbow Surgeons; Max, maximum; Min, minimum; N/A, not applicable; UCLA, University of California, Los Angeles.

follow-up. Six (11.8%) had slight or occasional pain, 4 (7.8%) admitted to pain with heavy activity, 4 (7.8%) reported pain with light activity, and 4 (7.8%) reported constant shoulder pain. Eight patients (15.7%) reported that they experienced cramping in the biceps area of the arm. Three reported that the pain occurred weekly, and 2 reported that the pain occurred on a monthly basis. Three reported cramping with heavy exercise. Nine patients (17.6%) reported subjective weakness with twisting motions such as turning a screwdriver or doorknob. These 9 patients reported that their arm that had undergone tenodesis was on average 27% weaker than their other arm. Forty-eight (94.1%) patients reported that they were satisfied with the surgery.

In a subgroup analysis comparing one group of patients who had either a rotator cuff repair or labral repair in addition to tenodesis with a second group of patients who did not have either of these additional procedures, we found no statistical significance in pre- or postoperative ASES scores or postoperative UCLA score (Table 4). Using a chi-square analysis, there was no significant difference between the 2 groups in the number of patients who reported that they had shoulder pain at last follow-up.

This cohort included 4 patients who had a workers' compensation claim. In subgroup analysis, there was no significant difference ($P > .05$) in outcome scores between patients with and without a workers' compensation claim.

DISCUSSION

The preferred location for biceps tenodesis and the decision between tenotomy and tenodesis are widely debated. We believe that the technique used in this cohort provides

TABLE 4

Outcome Scores in Subgroup Analysis^a

	Patients With Rotator Cuff Repair or Labrum Repair	Patients Without Rotator Cuff Repair or Labrum Repair	P
ASES score			
Preoperative	63.75 ± 10.69	67.32 ± 8.51	.2005
Postoperative	90.12 ± 10.51	83.48 ± 19.85	.1323
UCLA score			
Postoperative	30.75 ± 5.02	29.52 ± 6.39	.4457

^aValues are reported as mean ± SD. ASES, American Shoulder and Elbow Surgeons; UCLA, University of California, Los Angeles.

excellent biomechanical strength and clinical outcomes while decreasing the rate of complications such as the popeye deformity.

Biomechanical studies of various fixation techniques performed open^{25,29} or arthroscopically²⁶ have been conducted. Mazzocca et al¹⁸ compared open subpectoral bone tunnel fixation, arthroscopic interference screw fixation, open subpectoral interference screw fixation, and arthroscopic suture anchor fixation and found no statistically significant difference in ultimate failure strength between any of the techniques tested. Subpectoral bone tunnel fixation had a significantly higher mean cyclic displacement compared with the other techniques.¹⁸ Biomechanical testing has also shown equivalent pullout strength at traditional supraperacrotal and subpectoral locations with various interference screw designs.

The mean ultimate load to failure in group 1 of this study was 205 N (range, 110-443 N), and no specimens failed during cyclic testing. These results were consistent with other reports. In evaluation of 4 types of proximal biceps tenodesis methods, Patzer et al²⁶ found that the Bio-Tenodesis (Arthrex) screw had an ultimate failure load (UFL) of 218.3 N, and the Biceptor screw averaged 173.9 N. The difference was not statistically significant. Slabaugh et al³³ studied screw length and diameter of the Biceptor interference screw and had an average UFL of 177 N for an 8 × 25-mm screw placed in a traditional proximal location. Ozalay et al²⁴ studied the biomechanical strength of several tenodesis techniques in a sheep model and found the interference screw (Profile Screw; Depuy Orthotech Interference Screw System) technique, with placement at the inferior part of the biceps groove, to be the strongest construct, with a UFL of 243.3 N. While the threshold for sufficient pullout strength remains controversial, 112 N has been proposed.²² Nevertheless, the results from this study indicate a unique supraperacrotal biceps tenodesis location distal to the bicipital groove provides equivalent biomechanical strength as conventional proximal and subpectoral locations with interference screw fixation.

The clinical follow-up data from this cohort demonstrate a high level of postoperative satisfaction. The mean postoperative ASES and UCLA scores (87.1 and 30.2, respectively) are comparable or better than previously reported outcome scores for both tenotomy and tenodesis.^{11,13,14,19} Mazzocca et al¹⁹ previously reported a mean postoperative

ASES score of 81 in a series of 41 patients undergoing an open suprapectoral biceps tenodesis at an average of 29 months of follow-up. Similarly, Koh et al¹⁴ found a mean ASES score of 84.7 in 43 patients undergoing tenodesis, and a score of 79.6 in 41 patients undergoing tenotomy at a minimum of 2-year follow-up. Following biceps tenotomy, Kelly et al¹³ found a mean UCLA score of 27.6 and a mean ASES score of 75.6 in 54 patients at a minimum of 2-year follow-up, while Gill et al¹¹ found a mean ASES of 81.8 in 32 patients at an average of 19 months of follow-up.

Our cohort had a lower incidence of popeye deformity compared with other reports of biceps tenodesis outcomes. The rate of popeye deformity in our cohort was 2.0%, while the rate of popeye deformity in prior reports of tenodesis patients is 3% to 5%.^{5,21,27} The 1 patient in our cohort with a popeye deformity found the deformity to be cosmetically acceptable. The rate of popeye deformity in our patients is much lower than the previously reported rates of 62% to 80% in patients undergoing biceps tenotomy.^{5,21,27}

A reported concern with proximal biceps tenodesis techniques is that leaving the tendon in the bicipital groove may lead to a higher revision rate.³¹ Sanders et al³¹ found a significantly lower revision rate with tenodesis performed distal to the groove (7.7%) compared with proximal tenodesis techniques (20.6%). Furthermore, performing the tenodesis in the bicipital groove may not alleviate pain as the groove has been suggested as a potential pain generator.²⁸

The mini-open subpectoral techniques,^{20,28} which place the biceps tendon distal to the groove and below the pectoralis major, have distinct advantages over proximal tenodesis techniques.^{15,17} The primary advantages include preservation of the length-tension relationship of the biceps tendon and removal of the tendon from the groove to decrease persistent pain. However, a disadvantage of the open or mini-open distal tenodesis is a potential cosmetic deformity from the scar of the incision. The incisions are often 3 to 4 cm in length, which is larger than the incisions of the ports used in the all-arthroscopic technique.^{20,28} The longer incision could also have potential for increased blood loss and rates of infection.

Biceps tenodesis is commonly performed in conjunction with other arthroscopic procedures. During an otherwise all-arthroscopic procedure, the use of an open or mini-open tenodesis technique would usually require a separate instrument tray as well as additional operating room time for closure of the incision.⁸ Patients who require concomitant arthroscopic shoulder surgery would also require repositioning to accommodate an open subpectoral tenodesis. Finally, based on the cadaveric analysis by Jarrett et al,¹² a proximal tenodesis near the superior edge of the pectoralis tendon, which is performed in our all-arthroscopic technique, may better restore the natural muscle length-tension relationship than a distal subpectoral tenodesis.

Limitations

Our study has several limitations. First, it is retrospective and lacks a control group to offer a comparison. However, this study represents the largest cohort of patients using this biceps tenodesis technique, and our outcomes can be

compared with literature standards. Second, our follow-up period is relatively short, with a minimum of 10 months of follow-up. However, this coincides with typical recovery and return to function after such a procedure. Third, the variety of different additional shoulder procedures being performed at the time of tenodesis in our patient cohort serves as a possible confounding variable. Future studies are needed to assess the long-term outcome of this biceps tenodesis technique.

As with all procedures, there is a learning curve associated with the all-arthroscopic biceps tenodesis technique. In this clinical series, the senior surgeon transitioned from open to arthroscopic tenodesis technique without the need for converting any arthroscopic cases to open. The senior surgeon performed the procedure in a cadaver lab prior to using this technique with patients. We recommend that surgeons considering this technique gain skill with the procedure in a cadaver laboratory prior to using it in practice.

CONCLUSION

There are myriad options available to surgeons to address biceps tendon pathology. Although there is a learning curve involved, an all-arthroscopic suprapectoral technique with tenodesis between the subscapularis and pectoralis major may be an option to consider.

REFERENCES

- Ahrens PM, Boileau P. The long head of biceps and associated tendinopathy. *J Bone Joint Surg Br.* 2007;89:1001-1009.
- Amaravathi RS, Pankappilly B, Kany J. Arthroscopic keyhole proximal biceps tenodesis: a technical note. *J Orthop Surg (Hong Kong).* 2011; 19:379-383.
- Amstutz HC, Sew Hoy AL, Clarke IC. UCLA anatomic total shoulder arthroplasty. *Clin Orthop Relat Res.* 1981;(155):7-20.
- Barber A, Field LD, Ryu R. Biceps tendon and superior labrum injuries: decision-marking. *J Bone Joint Surg Am.* 2007;89:1844-1855.
- Boileau P, Baque F, Valerio L, Ahrens P, Chuinard C, Trojani C. Isolated arthroscopic biceps tenotomy or tenodesis improves symptoms in patients with massive irreparable rotator cuff tears. *J Bone Joint Surg Am.* 2007;89:747-757.
- Boileau P, Krishnan SG, Coste JS, Walch G. Arthroscopic biceps tenodesis: a new technique using bioabsorbable interference screw fixation. *Arthroscopy.* 2002;18:1002-1012.
- Cash DJ, Jones JW. The role of tenodesis in surgery of the upper limb. *J Bone Joint Surg Br.* 2011;93:285-292.
- David TS, Schildhorn JC. Arthroscopic suprapectoral tenodesis of the long head biceps: reproducing an anatomic length-tension relationship. *Arthrosc Tech.* 2012;1:e127-e132.
- Denard PJ, Dai X, Hanypsiak BT, Burkhart SS. Anatomy of the biceps tendon: implications for restoring physiological length-tension relation during biceps tenodesis with interference screw fixation. *Arthroscopy.* 2012;28:1352-1358.
- Frost A, Zafar MS, Maffulli N. Tenotomy versus tenodesis in the management of pathologic lesions of the tendon of the long head of the biceps brachii. *Am J Sports Med.* 2009;37:828-833.
- Gill TJ, McIrvine E, Mair SD, Hawkins RJ. Results of biceps tenotomy for treatment of pathology of the long head of the biceps brachii. *J Shoulder Elbow Surg.* 2001;10:247-249.
- Jarrett CD, McClelland WB Jr, Xerogeanes JW. Minimally invasive proximal biceps tenodesis: an anatomical study for optimal placement and safe surgical technique. *J Shoulder Elbow Surg.* 2011;20: 477-480.

13. Kelly AM, Drakos MC, Fealy S, Taylor SA, O'Brien SJ. Arthroscopic release of the long head of the biceps tendon: functional outcome and clinical results. *Am J Sports Med.* 2005;33:208-213.
14. Koh KH, Ahn JH, Kim SM, Yoo JC. Treatment of biceps tendon lesions in the setting of rotator cuff tears: prospective cohort study of tenotomy versus tenodesis. *Am J Sports Med.* 2010;38:1584-1590.
15. Lim TK, Moon ES, Koh KH, Yoo JC. Patient-related factors and complications after arthroscopic tenotomy of the long head of the biceps tendon. *Am J Sports Med.* 2011;39:783-789.
16. Lo IK, Burkhart SS. Arthroscopic biceps tenodesis using a bioabsorbable interference screw. *Arthroscopy.* 2004;20:85-95.
17. Lutton DM, Gruson KI, Harrison AK, Gladstone JN, Flatow EL. Where to tenodesis the biceps: proximal or distal? *Clin Orthop Relat Res.* 2011;469:1050-1055.
18. Mazzocca AD, Bicos J, Santangelo S, Romeo AA, Arciero RA. The biomechanical evaluation of four fixation techniques for proximal biceps tenodesis. *Arthroscopy.* 2005;21:1296-1306.
19. Mazzocca AD, Cote MP, Arciero CL, Romeo AA, Arciero RA. Clinical outcomes after subpectoral biceps tenodesis with an interference screw. *Am J Sports Med.* 2008;36:1922-1929.
20. Mazzocca AD, Rios CG, Romeo AA, Arciero RA. Subpectoral biceps tenodesis with interference screw fixation. *Arthroscopy.* 2005;21:896.
21. Nho SJ, Strauss EJ, Lenart BA, et al. Long head of the biceps tendinopathy: diagnosis and management. *J Am Acad Orthop Surg.* 2010;18:645-656.
22. Nordin M, Frankel V. Biomechanics of the elbow. In: Nordin M, Frankel V, eds. *Basic Biomechanics of the Musculoskeletal System.* 3rd ed. Philadelphia, PA: Lippincott Williams & Wilkins; 2001: 340-357.
23. Osbahr DC, Diamond AB, Speer KP. The cosmetic appearance of the biceps muscle after long-head tenotomy versus tenodesis. *Arthroscopy.* 2002;18:483-487.
24. Ozalay M, Akpınar S, Karaeminogullari O, et al. Mechanical strength of four different biceps tenodesis techniques. *Arthroscopy.* 2005;21:992-998.
25. Papp DF, Skelley NW, Sutter EG, et al. Biomechanical evaluation of open suture anchor fixation versus interference screw for biceps tenodesis. *Orthopedics.* 2011;34:e275-e278.
26. Patzer T, Rundic JM, Bobrowitsch E, Olender GD, Hurschler C, Schofer MD. Biomechanical comparison of arthroscopically performable techniques for supraperatorial biceps tenodesis. *Arthroscopy.* 2011;27:1036-1047.
27. Paulos LE, Mendez KT, Berg T. A novel approach to arthroscopic biceps tenodesis. *Oper Tech Sports Med.* 2007;15:27-34.
28. Provencher MT, LeClere LE, Romeo AA. Subpectoral biceps tenodesis. *Sports Med Arthrosc.* 2008;16:170-176.
29. Richards DP, Burkhart SS. A biomechanical analysis of two biceps tenodesis fixation techniques. *Arthroscopy.* 2005;21:861-866.
30. Richards RR, An KN, Bigliani LU, et al. A standardized method for the assessment of shoulder function. *J Shoulder Elbow Surg.* 1994;3:347-352.
31. Sanders B, Lavery KP, Pennington S, Warner JJ. Clinical success of biceps tenodesis with and without release of the transverse humeral ligament. *J Shoulder Elbow Surg.* 2012;21:66-71.
32. Scheibel M, Schroder RJ, Chen J, Bartsch M. Arthroscopic soft tissue tenodesis versus bony fixation anchor tenodesis of the long head of the biceps tendon. *Am J Sports Med.* 2011;39:1046-1052.
33. Slabaugh MA, Frank RM, Van Thiel GS, et al. Biceps tenodesis with interference screw fixation: a biomechanical comparison of screw length and diameter. *Arthroscopy.* 2011;27:161-166.
34. Slenker NR, Lawson K, Ciccotti MG, Dodson CC, Cohen SB. Biceps tenotomy versus tenodesis: clinical outcomes. *Arthroscopy.* 2012;28:576-582.